

Treatment of severe Crohn's disease using antimycobacterial triple therapy – approaching a cure?

T.J. Borody
S. Leis
E.F. Warren
R. Surace

Background. *Mycobacterium avium subspecies paratuberculosis* is probably the best candidate for a microbial cause of Crohn's disease although arguments to the contrary can be equally convincing. Growing evidence suggests that prolonged antimycobacterial combination therapy can improve Crohn's disease in some patients.

Aim. To report long-term observations in patients with severe Crohn's disease treated with triple macrolide-based antimycobacterial therapy.

Patients. A series of 12 patients (7 male, 5 female; aged 15-42 years) with severe, obstructive or penetrating Crohn's disease were recruited.

Methods. Patients failing maximal therapy were commenced prospectively on a combination of rifabutin (450 mg/d), clarithromycin (750 mg/d) and clofazimine (2 mg/kg/d). Progress was monitored through colonoscopy, histology, clinical response and Harvey-Bradshaw activity index.

Results. Follow-up data were available for up to 54 months of therapy. Six out of 12 patients experienced a full response to the anti-*Mycobacterium avium subspecies paratuberculosis* combination achieving complete clinical, colonoscopic and histologic remission of Crohn's disease. Four of these patients were able to cease treatment after 24-46 months, 3 of whom remained in total remission without treatment for up to 26 months and one patient relapsed after six months off treatment. A partial response to the anti-*Mycobacterium avium subspecies paratuberculosis* combination was seen in 2 patients showing complete clinical remission with mild histologic inflammation. Return to normal of terminal ileal strictures occurred in 5 patients. Harvey-Bradshaw activity index in patients showing a full or partial response to therapy fell from an initial 13.4 ± 1.91 to 0.5 ± 0.47 ($n=8$, $p<0.001$) after 52-54 months.

Conclusions. Reversal of severe Crohn's disease has been achieved in 6/12 patients using prolonged combination anti-*Mycobacterium avium subspecies paratuberculosis* therapy alone. Three patients remain in long-term remission with no detectable Crohn's disease off all therapy. These results support a causal role for *Mycobacterium avium subspecies paratuberculosis* in Crohn's disease while also suggesting that a cure may become possible.

From

Centre for Digestive Diseases, Sydney, Australia.

Address for correspondence

Dr. T.J. Borody, Centre for Digestive Diseases, 144 Great North Rd, Five Dock NSW 2046, Australia.
Fax: +61-2-97121675.
E-mail: tborody@zip.com.au

Submitted May 5, 2001

Accepted after revision September 25, 2001

Digest Liver Dis 2002;34:29-38

Key words: Crohn's disease; *Mycobacterium avium* ssp. *paratuberculosis*

Introduction

Controversy surrounds the concept of an infective cause for Crohn's disease (CD). Accumulating microbiological, immunological, molecular and epidemiological evidence is tipping the scales in favour of *Mycobacterium avium subspecies paratuberculosis* (MAP) as the primary aetiological agent in at least a proportion of patients with CD^{1,2}. This evidence includes

positive culture and polymerase chain reaction (PCR) detection of *MAP* in resected specimens from CD patients³⁻¹². *MAP* has been shown to cause ileocolitis in primates¹³. *MAP* has been found in pasteurised commercial milk and the breast milk of lactating Crohn's patients¹⁴⁻¹⁶. Recent studies have reported immunological responses to *MAP* in Crohn's sufferers¹⁷⁻¹⁹. On the other hand, many studies have failed to establish a firm relationship between *MAP* and CD and hence the wider scientific community remains sceptical towards its causative role²⁰⁻²¹.

CD resembles human intestinal tuberculosis and shares similarities with Johne's disease in cattle. Therefore, it is not surprising that trials using antimycobacterial drugs have been attempted in the past. Numerous case reports and open studies have shown some improvement in a sub-group of patients with CD using standard anti-tuberculous therapies²²⁻²⁶. These improvements however, were not lasting nor resulting in cure. Similarly, randomised controlled trials of various standard antimycobacterial drug combinations have failed to demonstrate long-lasting benefits in Crohn's patients²⁷⁻³¹.

Given that *MAP* is more closely related to *Mycobacterium avium* complex (MAC) than *Mycobacterium tuberculosis*, lessons from the treatment of MAC should apply to the treatment of *MAP*. Recent advances in the treatment of MAC infection and the availability of novel antimycobacterial agents have opened opportunities to combat *MAP*. Specifically, the chemical derivative of rifamycin antibiotics, rifabutin, and the macrolide, clarithromycin, have good activity against MAC and *MAP* in vitro both alone and in combination with other agents³²⁻³⁷. The dual combination of rifabutin and clarithromycin has been shown to be particularly effective³⁸⁻⁴⁰. Drugs of this type can target intracellular *MAP* because they are concentrated within macrophages and other host cells⁴¹⁻⁴³. In 1997, Gui et al. conducted a two-year outcome study of 46 CD patients using a combination of rifabutin and clarithromycin or azithromycin. They demonstrated a highly significant improvement in Harvey-Bradshaw activity index and inflammatory parameters at six months that were then maintained at two years⁴⁴.

As a result of the evolution of our understanding of *MAP* and MAC infections and given that mycobacterial infections require long-term therapy with at least three antimycobacterial agents, we initiated a pilot study of 'triple' antimycobacterial therapy in patients with severe and unresponsive CD using clarithromycin, rifabutin and clofazimine. Clofazimine was added to the combination as the third drug because like rifabutin and clarithromycin, it inhibits mycobacterial DNA transcription, making it effective against cell wall deficient forms of *MAP*.

Patients and methods

This is a prospective, open label pilot study of twelve patients (7 male, 5 female; aged 15-42 years) who were referred to the Centre for Digestive Diseases. Inclusion criteria selected for patients with an established diagnosis of obstructive or penetrating large or small bowel CD with the presence of persistent severe symptoms, active inflammation on colonoscopy and histology, and a Harvey-Bradshaw index⁴⁵ score greater than 5. All patients were failing or had failed the maximum dose of standard CD therapies. Patients were excluded due to pregnancy, non-compliance, or known adverse reaction or hypersensitivity to any related drug.

Patient pre-entry characteristics are outlined in Table I. Previous treatments, for all patients, included high-dose steroids, azathioprine and 5-aminosalicylic acid (5-ASA) compounds including sulphasalazine, mesalazine and/or olsalazine. One patient (n. 3) had previously received 6-mercaptopurine in addition to the other standard CD medications. Six patients (nos. 2, 3, 5, 7, 11, 12) had previously taken metronidazole, three (nos. 2, 11, 12) had taken clarithromycin and one (n. 8) a combination of metronidazole and ciprofloxacin. Five patients had undergone surgery before commencing anti-*MAP* therapy (Table I). At the commencement of therapy all patients were taking prednisone and 5-ASA compounds with or without azathioprine.

The treatment period was planned for 24 months, however being a pilot study extension was granted depending on individual response to therapy. Pre-study criteria for a response were defined as a 50% or greater reduction in symptoms of abdominal pain, urgency, stool frequency and passage of blood while on anti-*MAP* therapy alone. A full response was characterised by the induction of complete clinical, colonoscopic and histological remission of CD using anti-*MAP* therapy alone, while a partial response was defined as the achievement of clinical and colonoscopic remission but with mild histological inflammation.

Anti-*MAP* treatment comprised a combination of rifabutin 150 mg/d increasing to 450 mg/d by week 8 (Mycobutin, Pharmacia Corporation, Sydney, Australia), clarithromycin 250 mg/d increasing to 750 mg/d by week 8 (Klacid, Abbott, Sydney, Australia) and clofazimine 2 mg/kg – maximum 100 mg/d (Lamprene, Novartis Pharmaceuticals, Sydney, Australia). Azathioprine was terminated immediately. 5-ASA compounds were ceased at 6 weeks. Prednisone was decreased to zero at a rate of 5 mg per 2 weeks to avoid rapid steroid withdrawal. Milk and dairy product consumption was prohibited during the study, with the exception of ultra high temperature (UHT) milk, due to the theoretical possibility of re-infection with *MAP*.

Table 1. Patient pre-entry characteristics.

| Patient n. | Age (yrs) | Sex | Disease sites | Previous surgery | Duration of disease | Hb (g/l) | ESR (mm/hr) | CRP (mg/l) | H-B index | Colonoscopy |
|------------|-----------|-----|---------------------------|----------------------------------|---------------------|----------|-------------|------------|-----------|--|
| 1 | 42 | F | Colon | - | 15 mos | 129 | 7 | 1 | 26 | Pseudopolyps and deep ulcers |
| 2 | 29 | M | Terminal ileum | - | 2 yrs | 158 | 4 | 2 | 6 | Ileal stricture and gross ileitis |
| 3 | 27 | F | Terminal ileum* | - | 2 yrs | 92 | 17 | 23 | 13 | Ileal stricture and deep ulcers |
| 4 | 22 | F | Small bowel | 8 stricturoplasties | 2 yrs | 110 | 1 | 1 | 10 | Ileal stricture and scarring |
| 5 | 34 | M | Colon and rectum | Ischiorectal abscess and fistula | 15 yrs | 147 | 1 | 5 | 15 | Extensive pseudopolyps and deep colonic ulcers |
| 6 | 25 | M | Caecum and terminal ileum | - | 6 yrs | 147 | 10 | 1 | 13 | Ileal stricture and deep caecal ulcers |
| 7 | 25 | F | Terminal ileum* | - | 5 yrs | 116 | 27 | 11 | 13 | Ileal stricture |
| 8 | 42 | M | Rectum | Ischiorectal abscess | 14 mos | 131 | 28 | 1 | 11 | Pseudopolyps and deep rectal ulcers |
| 9 | 15 | F | Colon and terminal ileum | - | 5 yrs | 122 | 20 | 51 | 19 | Deep colonic ulcers |
| 10 | 26 | M | Small bowel and caecum | Hemicolectomy | 14 yrs | 77 | 17 | 22 | 18 | Jejunitis |
| 11 | 29 | M | Colon | Ileostomy | 12 mos | 121 | 17 | - | 27 | Necrotic mucosa and inflammation |
| 12 | 15 | M | Colon | - | 2 yrs | 124 | 39 | 57 | 15 | Colonic strictures and inflammation |

* total parenteral nutrition (TPN) required; abbreviations: see list.

Baseline tests included full blood count, erythrocyte sedimentation rate (ESR), C-reactive protein (CRP), iron studies, colonoscopy and histology, labelled leucocyte inflammatory scan, small bowel enema and cross-sectional ultrasound of the terminal ileum where applicable. These parameters were measured at 4-monthly intervals to determine patient progress. In addition, all patients underwent a 4-weekly clinical review to monitor symptoms. The Harvey-Bradshaw activity index was used throughout this study to measure clinical response.

Student t-test was performed to compare mean values of the Harvey-Bradshaw index score in patient groups before and after anti-MAP therapy.

Results

Clinical and colonoscopic response to anti-MAP therapy

Follow-up data were available for up to 54 months of anti-MAP therapy. Marked clinical improvement occurred in every patient within 6-8 weeks of commencing treatment, by which time all patients had ceased steroids, azathioprine and 5-ASA drugs and continued on the anti-MAP combination alone. By 6 months, ten patients claimed near-complete symptom control on anti-MAP therapy alone while the other two patients

(nos. 9, 12) experienced recrudescence of rectal bleeding and diarrhoea. Individual patient use of anti-MAP therapy is illustrated in Figure 1.

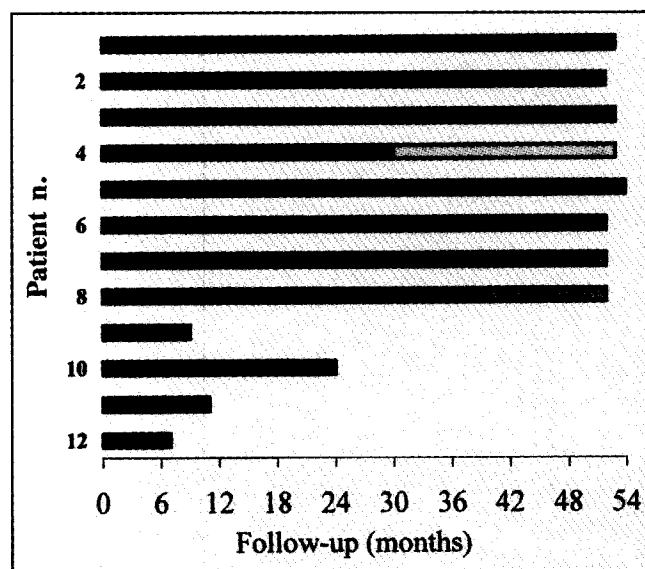
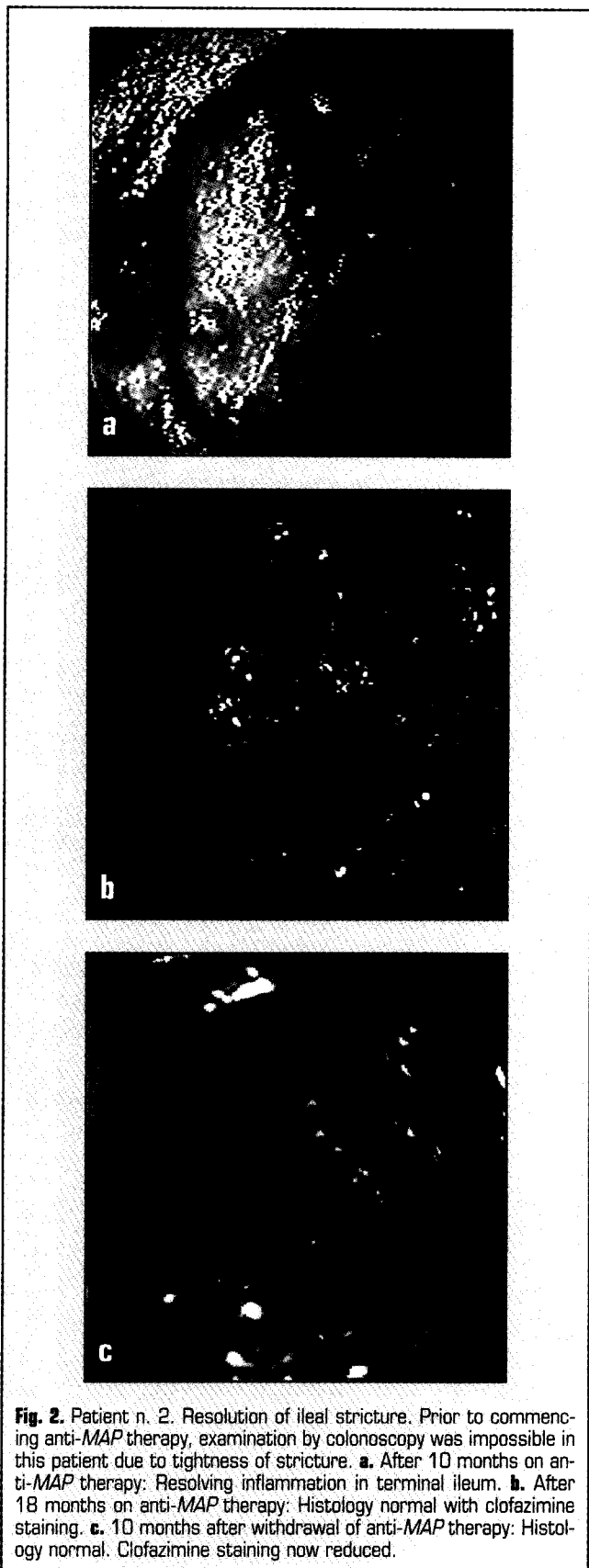


Fig. 1. Individual patient response to anti-MAP therapy (52-54 month follow-up). ■ Anti-MAP therapy alone; ■ Anti-MAP therapy ceased - well; □ Relapse: Anti-MAP therapy recommenced + azathioprine; ■ Anti-MAP therapy + azathioprine + 5-ASA.

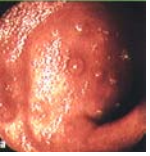


Nine out of twelve patients continued on anti-*MAP* therapy alone for at least 24 months. Patients 1-6 experienced a full response to treatment achieving complete clinical, colonoscopic and histological remission of CD. Patients 7 and 8 showed a partial response to therapy remaining in clinical remission with ongoing mild histological inflammation. Patient 10 developed a jejunal stricture and was withdrawn from anti-*MAP* treatment at 24 months. Three patients (nos. 9, 11, 12) ceased the anti-*MAP* combination prior to the conclusion of the planned treatment period due to clinical relapse and lack of colonoscopic and histological improvement.

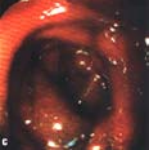
Anti-*MAP* treatment was extended beyond the planned 24-month period in 8 patients. Patients 1-4 ceased medication after 27, 29, 46 and 24 months, respectively. At the time this paper was submitted for publication, patients 1-3 remained clinically, colonoscopically and histologically disease-free at 26, 23 and 7 months post-cessation of treatment. Patient 4 relapsed 6 months after terminating treatment and colonoscopy revealed evidence of distal colitis though she had previously suffered from small bowel CD. This patient was subsequently recommenced on anti-*MAP* therapy in combination with low-dose azathioprine and after a further 20 months was clinically and colonoscopically normal. Patients 5 and 6 continued in total clinical, colonoscopic and histological remission after 54 and 52 months of anti-*MAP* therapy alone. Patients 7 and 8 were in clinical remission at 52 months with ongoing mild histological inflammation. They continued on anti-*MAP* therapy although low-dose azathioprine and 5-ASA compounds were introduced for symptomatic relief after 40 and 33 months, respectively.

Five patients initially presented with ileal strictures (two requiring total parenteral nutrition) which all resolved to become normal, both colonoscopically and in wall thickness on cross-sectional ultrasound examination. In patient 2, terminal ileum wall thickness was 11 mm initially and progressively recovered to 3 mm. Figure 2 shows how, over the course of 28 months, this stricture progressively dilated, regained vigorous motility, normal appearance, and normal histology which was maintained even after ceasing anti-*MAP* therapy. Such normalised motility was observed in all five patients with ileal strictures listed in Table I.

Six patients initially presented with deep ulcers (Table I). Of the six, 3 had ulcers in the colon. Complete resolution of these deep colonic ulcers was observed in patients 1 and 5 (see example, Fig. 3). Ulcers in the colon of patient 9, however, had failed to regress by the time this patient was withdrawn from the study. Patient 3 presented with ulcers in the terminal ileum which progressively recovered to normal



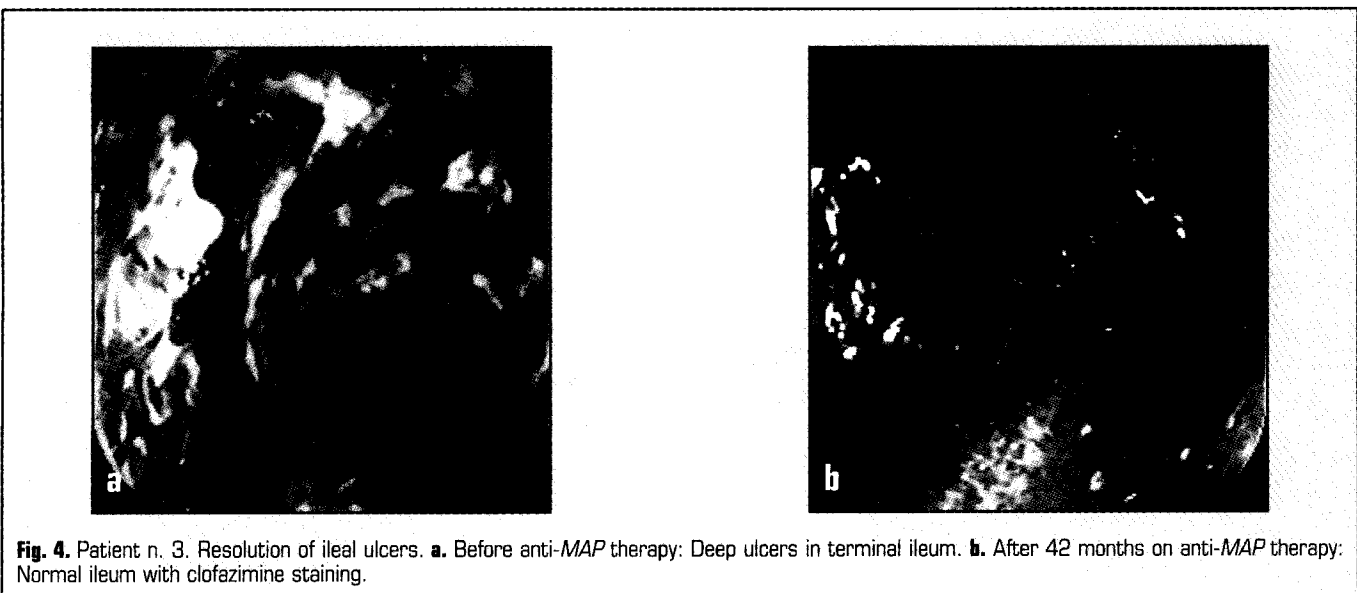
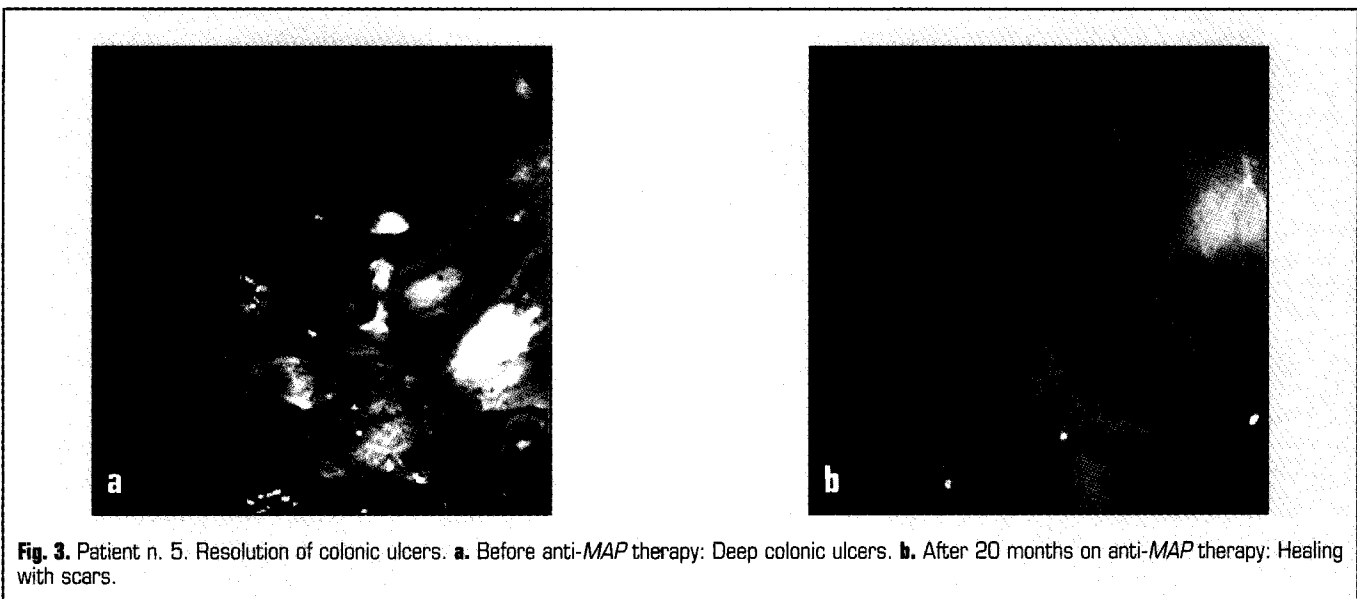


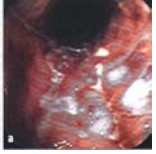

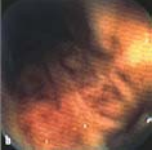
colonoscopic and histological appearance as demonstrated in Figure 4. Similarly, ulcers in the caecum of patient 6 and the large ulcer crater in the rectum of patient 8 resolved completely.

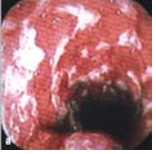Upon entering the study, pseudopolyps were identified in three patients. In patient 5, numerous crops of large pseudopolyps almost filling the colonic lumen progressively diminished and finally disappeared altogether (Fig. 5). A similar regression of pseudopolyps was observed in patient 1. After 40 months of anti-MAP therapy alone, pseudopolyps in the rectum of patient 8 remained.

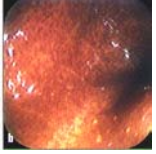
Treatment failure group Anti-MAP therapy was withdrawn in 4/12 patients. Patients 9 and 12 experienced symptom relapse and a fall in haematological parameters at 7 and 9 months requiring return to steroids and 5-ASA drugs and withdrawal of anti-MAP therapy. Patient 10 developed a jejunal stricture requiring resection after 24 months and was considered a treatment failure due to the presence of histological inflammation in the resected tissue. Patient 11 initially required an ileostomy due to severe pancolitis judged to be CD. This was rejoined 11 months after commencing therapy and medications were ceased. On











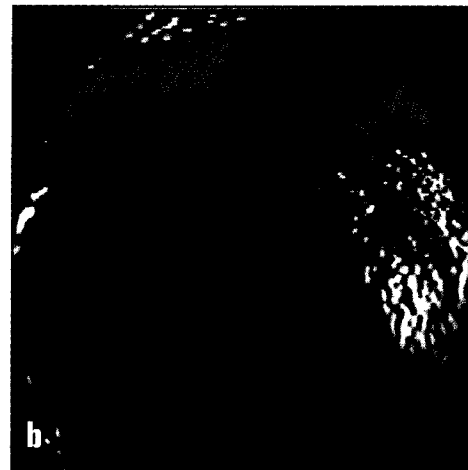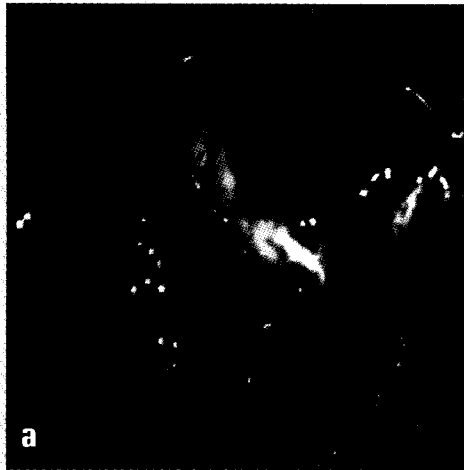


Fig. 5. Patient n. 5. Regression of pseudopolyp crops. **a.** Before anti-*MAP* therapy: Extensive pseudopolyps. **b.** After 20 months on anti-*MAP* therapy: Recovered mucosa.

re-colonoscopy, this patient was re-classified to ulcerative colitis and elected to proceed to ileo-anal anastomosis.

Harvey-Bradshaw activity index

The mean Harvey-Bradshaw activity index score for the group fell from 15.5 ± 1.71 (mean \pm standard error of the mean, $n=12$) to 2.0 ± 0.7 after 12 months ($p < 0.001$, $n=9$) and continued to fall during the course of treatment as shown in Figure 6. In patients with

long-term clinical remission (nos. 1-8) mean Harvey-Bradshaw index score fell from 13.4 ± 1.91 initially to 0.5 ± 0.47 after 52-54 months ($p < 0.001$).

Side-effects and compliance

The most common side-effect was a skin colouration resembling a fresh-red suntan which was seen to a varying degree in all patients. Eight patients developed arthralgia lasting between 2-12 weeks but required no therapy. Transient leucopenia was observed in five patients in the early stages of treatment. Four patients experienced dry skin, intermittently, for several months. De-pigmentation of the skin on hands and arms, similar to vitiligo, occurred in two patients, but later reversed. No uveitis was observed although orange-coloured urine was reported by all patients. One patient developed a 5-day episode of severe headaches early in the treatment requiring analgesics including codeine. Dark clofazimine staining was visible in the ileum of all those treated (Figs. 2, 3). This staining decreased markedly in two disease-free patients after ceasing therapy which is clearly demonstrated in Figure 2. No patient ceased therapy due to adverse drug reactions.

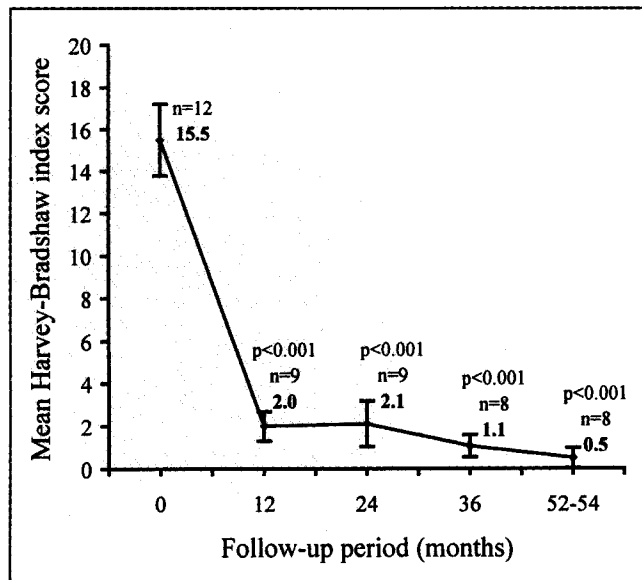
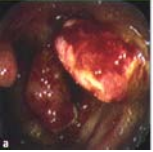
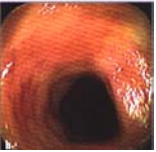


Fig. 6. Harvey-Bradshaw activity index scores at 12-month intervals over entire follow-up period (52-54 months). Values are shown as mean \pm standard error of mean and were compared with pre-treatment values using Student t-test.

Discussion

Several randomised controlled trials have evaluated the use of various antimycobacterial agents for the treatment of Crohn's disease. However, to date the results remain inconclusive²⁷⁻³¹. Explanations for this lack of uniform success may be based on the selection of inadequate drugs with poor intracellular penetration or





the application of insufficient treatment periods. This pilot study was carried out to determine whether long-lasting remission of CD could be achieved by treating the putative aetiological agent, *MAP*, for an extended period of time with three drugs known to be active against intracellular, atypical mycobacteria.

Initially, the treatment period was proposed for 24 months but due to early recurrence in one patient off therapy, the length of treatment was prolonged for up to 54 months in eight patients. To our knowledge, this is the longest documented antimycobacterial study period. The most conspicuous finding was that six patients became normal, clinically, colonoscopically and histologically, when treated with anti-*MAP* therapy alone. Four patients stopped all therapy after 24-46 months and three of these were totally free of CD up to 26 months later. At the time this paper was submitted for publication, two other patients continued on anti-*MAP* therapy alone and were colonoscopically and histologically normal. These results strengthen the hypothesis that *MAP* infection incites Crohn's disease in a proportion of patients and persists throughout the duration of disease. It thus follows that by eradicating *MAP*, using specific anti-*MAP* drugs, it might be possible to achieve a cure in these patients. This scenario resembles early reports of ulcer cure following eradication of *Helicobacter pylori* (*H. pylori*) which, at that time, was equally difficult to accept^{46,47}.

Recent reviews on the treatment of CD have suggested the combined use of anti-*MAP* therapy and immunosuppressive agents to cover both the potential infective pathogen and the inflammation^{1,48}. Encouraging results were obtained in this study with the late addition of azathioprine to the anti-*MAP* combination in the two partially responding patients and also in the patient who relapsed after ceasing anti-*MAP* drugs. Clinical normality and colonoscopic remission was regained in these three patients. This experience indicates that in those failing anti-*MAP* therapy alone, remission can again be achieved by adding azathioprine.

Several unique findings were documented in this study. Unlike the experience of Gui et al.⁴⁴ where surgery was required for strictures while on treatment, 5/5 terminal ileal strictures became normal during treatment. Two strictures were severe enough to initially require treatment with total parenteral nutrition. At serial colonoscopy, it was difficult to believe that tight strictures allowing only biopsy forceps to pass became progressively normal possessing vigorous motility which interfered with photography. Four out of five of these patients may attribute this success to the use of anti-*MAP* treatment alone. Gui et al.⁴⁴ noted that surgical resection of fibrous strictures followed anti-*MAP* therapy. We observed this in one patient with a distal jejunal stricture which was fibrotic and still inflamed.

Further unusual results included the resolution of deep ulcers in five patients and the complete disappearance of pseudopolyps in two using the anti-*MAP* combination. Anti-*MAP* therapy alone is responsible for the healing of ulcers in four out of five of these patients, while one patient was taking anti-*MAP* in combination with azathioprine in the later stages of treatment. The total regression of pseudopolyps is attributed to the use of anti-*MAP* therapy alone. It appears here that anti-*MAP* therapy was effective where years of treatment with combinations of steroids, 5-ASA compounds, azathioprine and metronidazole had failed, again implicating *MAP* in aetiology.

Reasons for the failure of anti-*MAP* therapy to induce remission of disease in four patients remain unclear, but this could be due to the possibility that CD has several causes involving an interaction between infectious or environmental triggers, immune response and genetic susceptibility¹. One interpretation of the varying responses to our therapy is that the remission of CD was mediated by suppression of *MAP* in some (partial responders) and its eradication in others (full responders). *MAP* may cause CD in only a proportion of patients while some unknown aetiology is responsible for initiating disease in other Crohn's patients^{1,48}. The failure rate of this antimicrobial combination will decrease when techniques used to identify those patients with *MAP* infection before treatment are perfected.

Initial clinical improvement on anti-*MAP* therapy with later relapse strongly suggests the presence or development of resistant *MAP*. Two out of four patients with recurrent CD while on treatment had previously been exposed to a course of clarithromycin. A similar resistance has been observed when *Mycobacterium avium* complex is treated with clarithromycin alone or in combination⁴⁹⁻⁵¹. In other infections, resistance may also develop during treatment – for example, *H. pylori* on clarithromycin-based triple therapy^{52,53} or *Mycobacterium tuberculosis* on standard anti-tuberculous therapy⁵⁴. Perhaps prior exposure predisposes to resistance induction in anti-*MAP* therapy.

In the present study, the addition of clofazimine to the Gui et al.⁴⁴ dual combination aimed to minimise the development of resistance. Clofazimine concentrates within leucocytes and ileal epithelial cells where it can be seen colonoscopically to stain the terminal ileum (Figs. 2, 3). The high concentration of clofazimine in this area suggests this drug has a unique value in the treatment of CD especially since all patients with terminal ileal strictures were successful in complete histological and colonoscopic reversal of their condition. It has proven synergy with rifabutin and clarithromycin^{51,55,56}. If the marked improvement, in some of our cases of CD, is via eradication of *MAP*, it would now be prudent to use either three or perhaps

more anti-*MAP* agents in combination given the slow replication rate of mycobacteria^{36 55 56}. Similarly, macrolides and rifamycins, in single or dual combinations, should be avoided to prevent resistance development.

The dosing protocol used in this study appeared to result in a relatively small number of side-effects. No patient was withdrawn due to adverse effects, although the long-term safety of this therapy has not been established. Potential serious risks include leucopenia, arthralgia and uveitis. While arthralgia developed in 8 patients, it resolved spontaneously during treatment. Initial leucopenia was infrequent, perhaps due to the low starting doses of rifabutin and clarithromycin. Severe leucopenia has been observed in normal subjects given high initial doses⁵⁷. The most common side-effect in our study was a skin colouration described as a healthy tan, however, this was welcomed by these patients who often looked sickly and pale.

Antimicrobial therapy is known to influence the luminal flora. Though it could be speculated that the anti-*MAP* therapy acted on luminal flora to induce remission this is unlikely because luminal flora can generally be suppressed but not eradicated so that, upon cessation of drugs, CD would recur. If acting on luminal flora, such suppressive therapy would be more likely to benefit those patients with colonic disease where bowel flora predominates, whereas, in this study, the greatest improvements were observed in the small bowel. Furthermore, numerous studies have used complex antimicrobial combinations and should also have achieved marked remission if their effect was on the luminal flora. Nevertheless, categorical exclusion of some beneficial action via the luminal flora is not possible without directly studying the flora itself.

To our knowledge, this is the first study with colonoscopic and histological monitoring of inflammatory changes in response to prolonged anti-*MAP* therapy for CD. Although Gui et al.⁴⁴ treated 46 patients with two anti-*MAP* agents, the study lacked colonoscopic follow-up so anatomical 'cure' could not be demonstrated. In previous CD studies, improvement over placebo was accepted as evidence of efficacy of a new therapy. With the demonstration of prolonged colonoscopic and histologic absence of CD off therapy, as in this study, it seems likely that future use of clinical measures such as the Harvey-Bradshaw index and the Crohn's disease activity index (CDAI) will be of limited value. The future 'gold standard' of therapeutic success in CD may be the absence of inflammation, colonoscopically and histologically.

The ideal length of anti-*MAP* treatment required to eradicate *MAP* remains to be established. Therapeutic periods in previous antimycobacterial studies have resulted in varied and inconsistent success. In the present

study, the relapse of one apparently disease-free patient after ceasing therapy at 24 months suggests that this was an inadequate treatment period to eradicate *MAP*. The three patients who stopped all therapy and achieved long-term remission and possibly cure of CD were only able to do so after continuing beyond the planned 24-month treatment period. Further controlled studies should examine the effects of anti-*MAP* therapy over extended treatment periods.

Results from this and other studies^{44 58 59} suggest that we may be on the verge of achieving a cure of CD by using multiple anti-*MAP* therapy for prolonged periods. Given the severity of the CD on enrolment into this study and prior failure of immunosuppressant and anti-inflammatory therapy, this combination of three anti-*MAP* agents appears to have adequate clinical power to recommend it for a larger controlled trial. In addition, through using colonoscopic and histological parameters of success, we could now test smaller patient groups stratified according to penetrating and obstructing disease to compare different combinations of anti-*MAP* agents. As with MAC, a comparison of four versus five drugs would now seem a priority. At the same time, we need to pursue the identification, culture and sensitivity studies of *MAP*. However, given the technical difficulties, in this area, it is likely that effective anti-*MAP* combination therapies will be developed to cure a higher proportion of CD well before adequate sensitivity studies are available to us from *MAP* cultures. At the time of commencement of our study, reliable isolation of *MAP* from biopsy specimens was unavailable, although we did attempt to culture.

Conclusions

Results of this pilot study using specific anti-*MAP* drugs point strongly to *MAP* as a causal aetiological agent of CD at least in a proportion of patients and it now seems that a cure of Crohn's disease is closer to being a reality. We need to focus our efforts on finding the best combinations of intracellularly active anti-*MAP* agents given for prolonged periods of time, monitored by colonoscopic and histological appearance combined with standard clinical parameters such as the Harvey-Bradshaw index. Microbiological culture, sensitivities and PCR detection of *MAP* should constitute research run in parallel with clinical trials. Monitoring for the presence of *MAP* will be important in the future, although, at this time, this technology is available only in a few centres in the world. Hence, research into *MAP* and its drug sensitivity on the one hand, together with combination therapeutic trials on the other, will accelerate the arrival of a cure for CD.

List of abbreviations

5-ASA: 5-aminosalicylic acid; CD: Crohn's disease; CDA: Crohn's disease activity index; CRP: C-reactive protein; ESR: erythrocyte sedimentation rate; Hb: haemoglobin; H-B: Harvey-Bradshaw; PCR: polymerase chain reaction; TPN: total parenteral nutrition; UHT: ultra high temperature.

References

- 1 Chamberlain W, Graham DY, Hulten K, El-Zimaity HM, Schwartz MR, Naser S, et al. Mycobacterium avium subsp. paratuberculosis as one cause of Crohn's disease. *Aliment Pharmacol Ther* 2001;15:337-46.
- 2 Hermon-Taylor J. The causation of Crohn's disease and treatment with antimicrobial drugs. *Ital J Gastroenterol Hepatol* 1998;30:607-10.
- 3 Chiodini RJ, Van Kruiningen HJ, Merkal RS, Thayer WR, Couto JA. Characteristics of an unclassified Mycobacterium species isolated from patients with Crohn's disease. *J Clin Micro* 1984;20:966-71.
- 4 Gitnick G, Collins J, Beaman B, Brooks D, Arthur M, Imaeda T, et al. Preliminary report on isolation of patients suffering with Crohn's disease. *Dig Dis Sci* 1989;34:925-32.
- 5 Sanderson JD, Moss MT, Tizard MLV, Hermon-Taylor J. Mycobacterium paratuberculosis DNA in Crohn's disease tissue. *Gut* 1992;33:890-6.
- 6 Moss MT, Sanderson JD, Tizard MLV, Hermon-Taylor J, El-Zatari FA, Markesich DC, et al. Polymerase chain reaction detection of Mycobacterium paratuberculosis and Mycobacterium avium subsp. silvaticum in long term cultures from Crohn's disease and control tissues. *Gut* 1992;33:1209-13.
- 7 Wall S, Kunze ZM, Saboor S, Soufleri J, Speechum P, Chiodini R, et al. Identification of spheroplast-like agents isolated from tissues of patients with Crohn's disease and control tissues by polymerase chain reaction. *J Clin Micro* 1993;31:1241-5.
- 8 Fidler HM, Thurell W, Johnson NMcl, Rook GAW, McFadden JJ. Specific detection of Mycobacterium paratuberculosis DNA associated with granulomatous tissue in Crohn's disease. *Gut* 1994;35:506-10.
- 9 Dell'Isola B, Poyart C, Goulet O, Mougnot J-F, Sadoun-Journo E, Brousse N, et al. Detection of Mycobacterium paratuberculosis by polymerase chain reaction in children with Crohn's disease. *J Infect Dis* 1994;169:449-51.
- 10 Lisby G, Andersen J, Engbaek K, Binder V. Mycobacterium paratuberculosis in intestinal tissue from patients with Crohn's disease demonstrated by nested primer polymerase chain reaction. *Scand J Gastroenterol* 1994;29:923-9.
- 11 Suenaga K, Yokoyama Y, Okazaki K, Yamamoto Y. Mycobacteria in the intestine of Japanese patients with inflammatory bowel disease. *Am J Gastroenterol* 1995;90:76-80.
- 12 Mishina D, Katsel P, Brown ST, Gilberts ECAM, Greenstein RJ. On the etiology of Crohn's disease. *Proc Natl Acad Sci USA* 1996;93:9816-20.
- 13 Chiodini RJ, Van Kruiningen HJ, Merkal RS. Ruminant paratuberculosis (Johne's disease): the current status and future prospects. *Cornell Vet* 1984;74:218-62.
- 14 Sweeney RW, Whitlock RH, Rosenberger AE. Mycobacterium paratuberculosis cultured from milk and supramammary lymph nodes of infected asymptomatic cows. *J Clin Microbiol* 1992;30:166-71.
- 15 Collins MT. Mycobacterium paratuberculosis: a potential food-borne pathogen? *J Dairy Sci* 1997;80:3445-8.
- 16 Naser SA, Schwartz D, Shafran I. Isolation of Mycobacterium avium subsp. paratuberculosis from breast milk of Crohn's disease patients. *Am J Gastroenterol* 2000;95:1094-5.
- 17 El-Zatari FA, Naser SA, Hulten K, Burch P, Graham DY. Characterization of Mycobacterium paratuberculosis p36 antigen and its seroactivities in Crohn's disease. *Curr Microbiol* 1999;39:115-9.
- 18 Suenaga K, Yokoyama Y, Nishimori I, Shuichi S, Masanori M, Kazuichi O, Onishi S. Serum antibodies to Mycobacterium paratuberculosis in patients with Crohn's disease. *Dig Dis Sci* 1999;44:1202-7.
- 19 Collins M, Lisby G, Moser C, Chicks D, Christensen S, Reichelderfer M, et al. Results of multiple diagnostic tests for Mycobacterium avium subsp. paratuberculosis in patients with inflammatory bowel disease and in controls. *J Clin Micro* 2000;38:4373-81.
- 20 Van Kruiningen HJ. Lack of support for a common etiology in Johne's disease of animals and Crohn's disease in humans. *Inflamm Bowel Dis* 1999;5:183-91.
- 21 Hubbard J, Surawicz CM. Etiological role of mycobacterium in Crohn's disease: An assessment of the literature. *Dig Dis Sci* 1999;17:6-13.
- 22 Ward M, McManus JPA. Dapsone in Crohn's disease. *Lancet* 1975;1:1236-7.
- 23 Paris JC, Simon V, Paris J. Etude critique des effets de la medication antituberculeuse dans une serie de 52 cas de formes severes de la maladie de Crohn. *Ann Gastroenterol Hepatol* 1977;13:427-33.
- 24 Picciotto A, Gesu GP, Schito GC, Testa R, Varagona G, Celle G. Antimycobacterial chemotherapy in two cases of inflammatory bowel disease. *Lancet* 1988;1:536-7.
- 25 Hampson SJ, Parker MC, Saverymuttu SH, Joseph AE, McFadden J-J, Hermon-Taylor J. Quadruple antimycobacterial chemotherapy in Crohn's disease: results at 9 months of a pilot study in 20 patients. *Aliment Pharmacol Ther* 1989;3:343-52.
- 26 Jarnerot G, Rolny P, Wickbom G, Alemayehu G. Antimycobacterial therapy ineffective in Crohn's disease after a year. *Lancet* 1989;1:164-5.
- 27 Shaffer JL, Hughes S, Linaker BD, Baker RD, Turnberg LA. Controlled trial of rifampicin and ethambutol in Crohn's disease. *Gut* 1984;25:203-5.
- 28 Afdhal NH, Long A, Lennon J, Crowe J, O'Donoghue DP. Controlled trial of antimycobacterial therapy in Crohn's disease: clofazimine versus placebo. *Dig Dis Sci* 1991;36:449-53.
- 29 Prantera C, Kohn A, Mangiarotti R, Andreoli A, Luzi C. Antimycobacterial therapy in Crohn's disease: results of a controlled, double-blind trial with a multiple antibiotic regimen. *Am J Gastroenterol* 1994;89:513-8.
- 30 Swift GL, Srivastava ED, Stone R, Pullan RD, Newcombe RG, Rhodes J, et al. Controlled trial of anti-tuberculous chemotherapy for two years in Crohn's disease. *Gut* 1994;35:363-8.
- 31 Thomas GAO, Swift GL, Green JT, Newcombe RG, Braniff-Mathews C, Rhodes J, et al. Controlled trial of antituberculous chemotherapy in Crohn's disease: a five year follow up study. *Gut* 1998;42:497-500.
- 32 Saito J, Sato K, Tomioka H. Comparative in vitro and in vivo activity of rifabutin and rifampicin against Mycobacterium avium complex. *Tubercle* 1988;69:187-92.
- 33 Onyeji CO, Nightingale CH, Tessier PR, Nicolau DP, Bow LM. Activities of clarithromycin, azithromycin and ofloxacin in combination with liposomal or unencapsulated granulocyte-macrophage colony-stimulating factor against intramacrophage Mycobacterium avium - Mycobacterium intracellulare. *J Infect Dis* 1995;172:810-6.

- ³⁴ Rastogi N, Labrousse V. Extracellular and intracellular activities of clarithromycin used alone and in association with ethambutol and rifampicin against *Mycobacterium avium* complex. *Antimicrob Agents Chemother* 1991;35:462-70.
- ³⁵ Piersimoni C, Tortoli E, Mascellino MT, Passerini Tosi C, Sbaragli G, Mandler F, et al. Activity of seven antimicrobial agents, alone and in combination, against AIDS-associated isolates of *Mycobacterium avium* complex. *J Antimicrob Chemother* 1995;36:497-502.
- ³⁶ Chiodini RJ. Antimicrobial activity of rifabutin in combination with two and three other antimicrobial agents against strains of *Mycobacterium paratuberculosis*. *J Antimicrob Chemother* 1991;27:171-6.
- ³⁷ Rastogi N, Goh KS, Labrousse V. Activity of clarithromycin compared with those of other drugs against *Mycobacterium paratuberculosis* and further enhancement of its extracellular and intracellular activities by ethambutol. *Antimicrob Agents Chemother* 1992;36:2843-6.
- ³⁸ Mor N, Vanderkolk J, Mezo N, Heifets L. Effects of clarithromycin alone and in combination on intracellular and extracellular replication of *Mycobacterium avium*. *Antimicrob Agents Chemother* 1994;38:2738-42.
- ³⁹ Fattorini L, Li B, Piersimoni C, Tortoli E, Xiao Y, Santoro C, et al. In vitro and ex vivo activities of antimicrobial agents used in combination with clarithromycin, with or without amikacin, against *Mycobacterium avium*. *Antimicrob Agents Chemother* 1995;39:680-5.
- ⁴⁰ Ghebremichael S, Svenson SB, Kallenius G, Hoffner SE. Antimycobacterial synergism of clarithromycin and rifabutin. *Scand J Infect Dis* 1996;28:387-90.
- ⁴¹ Gladue RP, Snider ME. Intracellular accumulation of azithromycin by cultured human fibroblasts. *Antimicrob Agents Chemother* 1990;34:1056-60.
- ⁴² Panteix G, Guillaumond B, Harf R, Desbos A, Sapin V, Leclercq M, Perrin-Fayolle M. In-vitro concentration of azithromycin in human phagocytic cells. *J Antimicrob Chemother* 1993;31(Suppl E):1-4.
- ⁴³ Frascini F, Scaglione F, Pintucci G, Maccarinelli G, Dugani S, Demartini G. The diffusion of clarithromycin and roxithromycin into nasal mucosa, tonsil and lung in humans. *J Antimicrob Chemother* 1991;27(Suppl A):61-5.
- ⁴⁴ Gui GPH, Thomas PRS, Tizard MLV, Lake J, Hermon-Taylor J. Two-year outcomes analysis of Crohn's disease treated with rifabutin and macrolide antibiotics. *J Antimicrob Chemother* 1997;39:393-400.
- ⁴⁵ Harvey RF, Bradshaw JM. A simple index of Crohn's-disease activity. *Lancet* 1980;1:514.
- ⁴⁶ Borody T, Daskalopoulos G, Brandl S, Carrick J, Hazell S. Dyspeptic symptoms improve following eradication of gastric *Campylobacter pyloridis*. *Gastroenterology* 1987;92:1324.
- ⁴⁷ George LL, Borody TJ, Andrews P, Devine M, Moore-Jones D, Walton M, Brandl S. Cure of duodenal ulcer after eradication of *Helicobacter pylori*. *Med J Aust* 1990;153:145-9.
- ⁴⁸ Hulten K, Ashraf A, Fouad AK, El-Zaatari FA, Graham DY. Antibacterial therapy for Crohn's disease: A review emphasizing therapy directed against mycobacteria. *Dig Dis Sci* 2000;45:445-56.
- ⁴⁹ Doucet-Populaire F, Truffot-Pernot C, Grosset J, Jarlier V. Acquired resistance in *Mycobacterium avium* complex strains isolated from AIDS patients and beige mice during treatment with clarithromycin. *J Antimicrob Chemother* 1995;36:129-36.
- ⁵⁰ Bermudez LE, Petrofsky M, Lolonoski P, Young LS. Emergence of *Mycobacterium avium* populations resistant to macrolides during experimental chemotherapy. *Antimicrob Agents Chemother* 1998;42:180-3.
- ⁵¹ Haefner M, Funke-Kissling P, Pfyffer GE, Luthy R, Opravil M. Clarithromycin, rifabutin and clofazimine for treatment of disseminated *Mycobacterium avium* complex disease in AIDS patients. *Clinical Drug Invest* 1999;17:171-8.
- ⁵² Adamek RJ, Suerbaum S, Pfaffenbach B, Opferkuch W. Primary and acquired *Helicobacter pylori* resistance to clarithromycin, metronidazole, and amoxicillin-influence on treatment outcome. *Am J Gastroenterol* 1998;93:386-9.
- ⁵³ Buckley MJ, Xia HX, Hyde DM, Keane CT, O'Morain CA. Metronidazole resistance reduces efficacy of triple therapy and leads to secondary clarithromycin resistance. *Dig Dis Sci* 1997;42:2111-5.
- ⁵⁴ Hariss KA Jr, Mukundan U, Musser JM, Kreiswirth BN, Lalitha MK. Genetic diversity and evidence for acquired antimicrobial resistance in *Mycobacterium tuberculosis* at a large hospital in South India. *Int J Infect Dis* 2000;4:140-7.
- ⁵⁵ Saito H, Saro K. Activity of rifabutin alone and in combination with clofazimine, kanamycin and ethambutol against *Mycobacterium intracellulare* infections in mice. *Tubercle* 1989;70:201-5.
- ⁵⁶ Yajko DM, Sanders A, Madej JJ, Cawthon L, Hadley K. In vitro activities of rifabutin, azithromycin, ciprofloxacin, clarithromycin, clofazimine, ethambutol and amikacin in combinations of two, three and four drugs against *Mycobacterium avium*. *Antimicrob Agents Chemother* 1996;40:743-9.
- ⁵⁷ Griffith DE, Brown BA, Girard WM, Wallace RJ Jr. Adverse events associated with high-dose rifabutin in macrolide-containing regimens for the treatment of *Mycobacterium avium* complex lung disease. *Clin Infect Dis* 1995;21:594-8.
- ⁵⁸ Borody TJ, Leis S, Surace R, Warren E, Lim E. Treatment of severe Crohn's disease using rifabutin-macrolide-clofazimine combination: results at 38-43 months. *J Gastroenterol Hepatol* 2000;15:J102.
- ⁵⁹ Douglass A, Cann PA, Bramble MG. An open pilot study of antimicrobial therapy in patients with unresponsive Crohn's disease. *Gut* 2000;46:A11.